

Package Title: Testbank
Course Title: pha14
Chapter Number: 01

Question type: Multiple Choice

1) The levels of structural organization from least complex to most complex are as follows:

- a) chemical, cellular, organ, tissue, system
- b) cellular, organ, chemical, tissue, system
- c) chemical, cellular, tissue, organ, system
- d) chemical, system, tissue, cellular, organ

Answer: c

Difficulty: Easy

Bloom's: Comprehension

Study Objective 1: SO 1.2 Identify the organ systems and major organs of the human body and describe their locations and functions.

Study Objective 2: SO 1.2.1 Describe the levels of structural organization that make up the human body.

Section Reference 1: Sec 1.2 Levels of Body Organization and Body Systems

2) The four basic types of tissues in the body are

- a) skeletal, muscular, epithelial, nervous
- b) connective, muscle, nervous, epithelial
- c) vascular, nervous, epithelial, connective
- d) muscle, nervous, skeletal, connective

Answer: b

Difficulty: Easy

Bloom's: Knowledge

Study Objective 1: SO 1.2 Identify the organ systems and major organs of the human body and describe their locations and functions.

Study Objective 2: SO 1.2.1 Describe the levels of structural organization that make up the human body.

Section Reference 1: Sec 1.2 Levels of Body Organization and Body Systems

3) The kidney is _____ to the stomach.

- a) Anterior
- b) Inferior
- c) Distal
- d) Dorsal

Answer: d

Difficulty: Medium

Bloom's: Application

Study Objective 1: SO 1.4 Describe the human body using the anatomical position and specific anatomical terminology.

Study Objective 2: SO 1.4.4 Define each directional term used to describe the human body.

Section Reference 1: Sec Exhibit 1.A Directional Terms

4) The word that best describes the position of the gallbladder relative to the ascending colon is

- a) contralateral
- b) ipsilateral
- c) inferior
- d) intermediate

Answer: b

Difficulty: Easy

Bloom's: Comprehension

Study Objective 1: SO 1.4 Describe the human body using the anatomical position and specific anatomical terminology.

Study Objective 2: SO 1.4.4 Define each directional term used to describe the human body.

Section Reference 1: Sec Exhibit 1.A Directional Terms

5) In the anatomical position, the palms of the hands face:

- a) Forward
- b) Posteriorly
- c) Laterally
- d) Medially

Answer: a

Difficulty: Easy

Bloom's: Comprehension

Study Objective 1: SO 1.4 Describe the human body using the anatomical position and specific anatomical terminology.

Study Objective 2: SO 1.4.1 Describe the orientation of the human body in the anatomical position.

Section Reference 1: Sec 1.4 Basic Anatomical Terminology

6) An accident report submitted by an officer who is a former anatomy student contains the following statement: "The victim suffered a severe blow to the mental region." This means

- a) the victim had a severe wound to the skull bones
- b) the victim's brain was obviously injured
- c) the victim was struck on the chin
- d) the victim witnessed a shocking event

Answer: c

Difficulty: Easy

Bloom's: Comprehension

Study Objective 1: SO 1.4 Describe the human body using the anatomical position and specific anatomical terminology.

Study Objective 2: SO 1.4.2 Relate the common names to the corresponding anatomical descriptive terms for various regions of the human body.

Section Reference 1: Sec 1.4 Basic Anatomical Terminology

7) A _____ section of the body or organ would reveal its right and left side

- a) sagittal
- b) frontal (coronal)
- c) oblique
- d) any of these choices

Answer: a

Difficulty: Medium

Bloom's: Application

Study Objective 1: SO 1.4 Describe the human body using the anatomical position and specific anatomical terminology.

Study Objective 2: SO 1.4.3 Define the anatomical planes, the anatomical sections, and the directional terms used to describe the human body.

Section Reference 1: Sec 1.4 Basic Anatomical Terminology

8) Name the two most specific body cavities that would be sectioned if a transverse plane were passed through the umbilicus.

- a) abdominal and pelvic
- b) pelvic and thoracic
- c) thoracic and vertebral canal

d) abdominal and vertebral canal

Answer: d

Difficulty: Hard

Bloom's: Evaluation

Study Objective 1: SO 1.5 Describe the major body cavities, the organs they contain, and their associated linings.

Section Reference 1: Sec 1.5 Body Cavities

9) Serous membranes are associated with the

- a) pleural cavity
- b) pericardial cavity
- c) abdominal cavity
- d) all of these choices

Answer: d

Difficulty: Easy

Bloom's: Comprehension

Study Objective 1: SO 1.5 Describe the major body cavities, the organs they contain, and their associated linings.

Section Reference 1: Sec 1.5 Body Cavities

10) Most specifically, the heart is located in the

- a) pericardial cavity
- b) thoracic cavity
- c) mediastinum
- d) all of these choices

Answer: a

Difficulty: Medium

Bloom's: Application

Study Objective 1: SO 1.5 Describe the major body cavities, the organs they contain, and their associated linings.

Section Reference 1: Sec 1.5 Body Cavities

11) Which of the following statements is false?

- a) the diaphragm separates the abdominal cavity from the pelvic cavity

- b) the esophagus is located in the mediastinum
- c) the vertebral canal contains the spinal cord
- d) the pleural cavities, containing the lungs, are part of the thoracic cavity

Answer: a

Difficulty: Medium

Bloom's: Analysis

Study Objective 1: SO 1.5 Describe the major body cavities, the organs they contain, and their associated linings.

Section Reference 1: Sec 1.5 Body Cavities

12) The word "dorsum" may be used to describe the

- 1. back of the hand
- 2. anterior surface of the body
- 3. top of the foot

- a) 1 only
- b) 2 only
- c) 3 only
- d) 1 and 3

Answer: d

Difficulty: Hard

Bloom's: Synthesis

Study Objective 1: SO 1.4 Describe the human body using the anatomical position and specific anatomical terminology.

Study Objective 2: SO 1.4.2 Relate the common names to the corresponding anatomical descriptive terms for various regions of the human body.

Section Reference 1: Sec 1.4 Basic Anatomical Terminology

13) What anatomical structure is being described using the following anatomical terms: medial to the ear (otic); lateral to the nose (nasal); inferior to the eye (orbital); and superior to the maxillary (upper) teeth?

- a) cheek (buccal)
- b) chin (mental)
- c) eyebrow
- d) forehead (frontal)

Answer: a

Difficulty: Hard

Bloom's: Evaluation

Study Objective 1: SO 1.4 Describe the human body using the anatomical position and specific anatomical terminology.

Study Objective 2: SO 1.4.4 Define each directional term used to describe the human body.

Section Reference 1: Sec 1.4 Basic Anatomical Terminology

14) The two organ systems that have the primary responsibility for regulating body activities are

- a) lymphatic and endocrine
- b) nervous and endocrine
- c) nervous and lymphatic
- d) endocrine and respiratory

Answer: b

Difficulty: Medium

Bloom's: Analysis

Study Objective 1: SO 1.2 Identify the organ systems and major organs of the human body and describe their locations and functions.

Study Objective 2: SO 1.2.2 Outline the 11 systems of the human body, list the organs present in each, and explain their general functions.

Section Reference 1: Sec 1.2 Levels of Body Organization and Body Systems

15) A transverse plane

- 1. is also known as the coronal plane
- 2. is also known as a horizontal plane or cross-sectional plane
- 3. divides the body into right and left sections

- a) 1 only
- b) 2 only
- c) 3 only
- d) both 2 and 3 are correct

Answer: b

Difficulty: Medium

Bloom's: Application

Study Objective 1: SO 1.4 Describe the human body using the anatomical position and specific anatomical terminology.

Study Objective 2: SO 1.4.3 Define the anatomical planes, the anatomical sections, and the directional terms used to describe the human body.

Section Reference 1: Sec 1.4 Basic Anatomical Terminology

16) Name the first form of medical imaging used to look at gross structures inside the body. It has been used in medicine since the 1940s and provides 'pictures' of internal structures in two-dimensional images where bones appear white, hollow structures (e.g. lungs) appear black, and structures of intermediate density (e.g. skin, fat, and muscle) appear as varying shades of gray.

- a) magnetic resonance imaging
- b) computed tomography
- c) radiography
- d) ultrasound scanning

Answer: c

Difficulty: Easy

Bloom's: Knowledge

Study Objective 1: SO 1.9 Describe the principles of medical imaging procedures and their importance in the evaluation of organ functions and the diagnosis of disease.

Section Reference 1: Sec 1.9 Medical Imaging

17) The transformation of a single fertilized human egg cell into a unique individual is a good example of what human life process?

- a) metabolism
- b) responsiveness
- c) differentiation
- d) movement

Answer: c

Difficulty: Medium

Bloom's: Application

Study Objective 1: SO 1.3 Define the important life processes of humans.

Section Reference 1: Sec 1.3 Life Processes

18) Food proteins are broken down into amino acids, building blocks that can then be used to build new proteins that make up muscles and bones. This is a good example of what human life process?

- a) movement
- b) reproduction
- c) differentiation
- d) metabolism

Answer: d

Difficulty: Medium

Bloom's: Application

Study Objective 1: SO 1.3 Define the important life processes of humans.

Section Reference 1: Sec 1.3 Life Processes

19) From the following list, which would be considered a “symptom” of an illness rather than a “sign?”

- a) blood pressure
- b) heart rate
- c) anxiety
- d) fever

Answer: c

Difficulty: Hard

Bloom's: Evaluation

Study Objective 1: SO 1.7 Distinguish between a symptom and a sign of a disease.

Section Reference 1: Sec 1.7 The Human Body and Disease

20) Which of the following imaging procedures is best used to study the physiology of body structures, such as metabolism of the brain or heart?

- a) sonography
- b) MRI
- c) CT
- d) none of these choices

Answer: d

Difficulty: Medium

Bloom's: Application

Study Objective 1: SO 1.9 Describe the principles of medical imaging procedures and their importance in the evaluation of organ functions and the diagnosis of disease.

Section Reference 1: Sec 1.9 Medical Imaging

Question type: True/False

21) Gross anatomy involves the microscopic study of the structure of tissues.

Answer: False

Difficulty: Easy

Bloom's: Knowledge

Study Objective 1: SO 1.1 Define anatomy and physiology, and name several branches of anatomy.

Section Reference 1: Sec 1.1 Anatomy Defined

22) The lymphatic system is responsible for the transportation of oxygen and carbon dioxide between the lungs and body tissues.

Answer: False

Difficulty: Easy

Bloom's: Knowledge

Study Objective 1: SO 1.2 Identify the organ systems and major organs of the human body and describe their locations and functions.

Study Objective 2: SO 1.2.2 Outline the 11 systems of the human body, list the organs present in each, and explain their general functions.

Section Reference 1: Sec 1.2 Levels of Body Organization and Body Systems

23) The antebrachial region is distal to the antecubital region.

Answer: True

Difficulty: Medium

Bloom's: Application

Study Objective 1: SO 1.4 Describe the human body using the anatomical position and specific anatomical terminology.

Study Objective 2: SO 1.4.4 Define each directional term used to describe the human body.

Section Reference 1: Sec Exhibit 1.A Directional Terms

24) The patellar region is superior to the inguinal region.

Answer: False

Difficulty: Easy

Bloom's: Knowledge

Study Objective 1: SO 1.4 Describe the human body using the anatomical position and specific anatomical terminology.

Study Objective 2: SO 1.4.4 Define each directional term used to describe the human body.

Section Reference 1: Sec Exhibit 1.A Directional Terms

25) The knee is proximal to the ankle.

Answer: True

Difficulty: Easy

Bloom's: Comprehension

Study Objective 1: SO 1.4 Describe the human body using the anatomical position and specific anatomical terminology.

Study Objective 2: SO 1.4.4 Define each directional term used to describe the human body.

Section Reference 1: Sec Exhibit 1.A Directional Terms

26) The hypogastric region is lateral to the hypochondriac region.

Answer: False

Difficulty: Easy

Bloom's: Comprehension

Study Objective 1: SO 1.6 Name and describe the abdominopelvic regions and the abdominopelvic quadrants.

Section Reference 1: Sec 1.6 Abdominopelvic Regions and Quadrants

27) The epigastric region is superior to the hypogastric region.

Answer: True

Difficulty: Easy

Bloom's: Comprehension

Study Objective 1: SO 1.6 Name and describe the abdominopelvic regions and the abdominopelvic quadrants.

Section Reference 1: Sec 1.6 Abdominopelvic Regions and Quadrants

28) The mediastinum contains the heart, lungs, trachea, esophagus, and major blood vessels.

Answer: False

Difficulty: Medium

Bloom's: Application

Study Objective 1: SO 1.5 Describe the major body cavities, the organs they contain, and their associated linings.

Section Reference 1: Sec 1.5 Body Cavities

29) The serous membrane associated with the lungs is called the pleural membrane.

Answer: True

Difficulty: Easy

Bloom's: Knowledge

Study Objective 1: SO 1.5 Describe the major body cavities, the organs they contain, and their associated linings.

Section Reference 1: Sec 1.5 Body Cavities

30) The descending colon of the large intestine extends from the left lumbar region into the left iliac region.

Answer: True

Difficulty: Medium

Bloom's: Application

Study Objective 1: SO 1.6 Name and describe the abdominopelvic regions and the abdominopelvic quadrants.

Section Reference 1: Sec 1.6 Abdominopelvic Regions and Quadrants

31) The body's ability to detect and react to changes in its internal and external environment is referred to as "responsiveness."

Answer: True

Difficulty: Easy

Bloom's: Knowledge

Study Objective 1: SO 1.3 Define the important life processes of humans.

Section Reference 1: Sec 1.3 Life Processes

32) A patient suffering from a sinus infection would be treated for a systemic illness.

Answer: False

Difficulty: Easy

Bloom's: Comprehension

Study Objective 1: SO 1.7 Distinguish between a symptom and a sign of a disease.

Section Reference 1: Sec 1.7 The Human Body and Disease

33) A patient's vital signs (height, weight, temperature) will most likely be measured and reported in meters, kilograms and centigrade, respectively.

Answer: True

Difficulty: Medium

Bloom's: Application

Study Objective 1: SO 1.10 Explain the importance of measurements in the evaluation of the human body.

Section Reference 1: Sec 1.10 Measuring the Human Body

Question type: Essay

34) List the components of the following major systems and give two functions of each system: skeletal, muscular, digestive, respiratory, nervous, urinary.

Answer:

Difficulty: Medium

Bloom's: Application

Study Objective 1: SO 1.2 Identify the organ systems and major organs of the human body and describe their locations and functions.

Study Objective 2: SO 1.2.2 Outline the 11 systems of the human body, list the organs present in each, and explain their general functions.

Section Reference 1: Sec 1.2 Levels of Body Organization and Body Systems

Solution: See Table 1.2 for a summary of components and functions.

35) Describe three functions of the lymphatic system.

Answer:

Difficulty: Medium

Bloom's: Application

Study Objective 1: SO 1.2 Identify the organ systems and major organs of the human body and describe their locations and functions.

Study Objective 2: SO 1.2.2 Outline the 11 systems of the human body, list the organs present in each, and explain their general functions.

Section Reference 1: Sec 1.2 Levels of Body Organization and Body Systems

Solution: (1) delivers interstitial fluid to the blood (2) transports lipids from the GI tract to the blood (3) is the site of most immune reactions

36) Describe the structure of a serous membrane including the names of the individual layers. Name three important serous membranes in the body and list the organ(s) they surround.

Answer:

Difficulty: Medium

Bloom's: Application

Study Objective 1: SO 1.5 Describe the major body cavities, the organs they contain, and their associated linings.

Section Reference 1: Sec 1.5 Body Cavities

Solution: A serous membrane is a double-layered membrane where one layer adheres to the organ (visceral layer) and one layer adheres to the body wall (parietal layer). The space in-between is filled with serous fluid which protects the layers from friction. The three serous membranes are the pleural membrane, pericardial membrane, and peritoneum.

37) Detective I. M. Smart (a former anatomy student) was called to investigate a murder scene. The victim was lying in a supine position, his glazed eyes staring skyward, legs together with toes pointing upward, arms by his sides, palms facing upward. Smart concluded that the victim was found in the anatomical position. Was he correct? Why or why not?

Answer:

Difficulty: Easy

Bloom's: Comprehension

Study Objective 1: SO 1.4 Describe the human body using the anatomical position and specific anatomical terminology.

Study Objective 2: SO 1.4.1 Describe the orientation of the human body in the anatomical position.

Section Reference 1: Sec 1.4 Basic Anatomical Terminology

Solution: No, he is not correct. In the anatomical position, the body is in an upright position.

38) Describe, in words, the frontal (coronal), transverse, midsagittal, and parasagittal planes. Now illustrate these planes by drawing a simple figure.

Answer:

Difficulty: Easy

Bloom's: Knowledge

Study Objective 1: SO 1.4 Describe the human body using the anatomical position and specific anatomical terminology.

Study Objective 2: SO 1.4.3 Define the anatomical planes, the anatomical sections, and the directional terms used to describe the human body.

Section Reference 1: Sec 1.4 Basic Anatomical Terminology

Solution: A frontal (coronal) plane divides the body into anterior and posterior portions. A transverse plane divides the body into superior and inferior sections. A midsagittal plane divides the body into equal right and left sides. A parasagittal plane divides the body into unequal right and left sides.

39) The abdominopelvic cavity is divided into nine regions. Using two vertical and two horizontal lines, label each region.

Answer:

Difficulty: Medium

Bloom's: Application

Study Objective 1: SO 1.6 Name and describe the abdominopelvic regions and the abdominopelvic quadrants.

Section Reference 1: Sec 1.6 Abdominopelvic Regions and Quadrants

Solution: See Figure 1.8

40) Explain why measurements are important when evaluating the status of the human body.

Answer:

Difficulty: Medium

Bloom's: Application

Study Objective 1: SO 1.10 Explain the importance of measurements in the evaluation of the human body.

Section Reference 1: Sec 1.10 Measuring the Human Body

Solution: Measurements enable us to describe the body and understand how it works. They allow medical professionals to determine the dosages of medication and to quantify variables such as weight, temperature, girth, etc

41) Distinguish between a "sign" and a "symptom" with respect to an illness.

Answer:

Difficulty: Medium

Bloom's: Analysis

Study Objective 1: SO 1.7 Distinguish between a symptom and a sign of a disease.

Section Reference 1: Sec 1.7 The Human Body and Disease

Solution: A symptom is a subjective change in body functions that is not apparent to an observer. Examples of symptoms are headache, nausea, and anxiety. Objective changes that a clinician can observe and measure are called signs. Signs of disease can be either anatomical or physiological.

42) A patient being imaged by MRI is not allowed to have any metal on him. Why?

Answer:

Difficulty: Medium

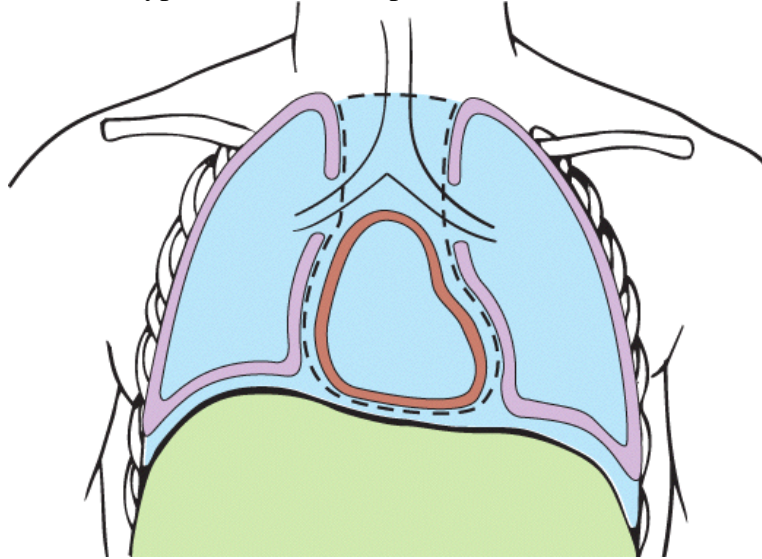
Bloom's: Application

Study Objective 1: SO 1.9 Describe the principles of medical imaging procedures and their importance in the evaluation of organ functions and the diagnosis of disease.

Section Reference 1: Sec 1.9 Medical Imaging

Solution: This is very dangerous since the body is exposed to a high-energy magnetic field in order to cause protons to arrange themselves in relation to the field.

43) What type of section was performed on this torso?



Answer:

Difficulty: Medium

Bloom's: Application

Study Objective 1: SO 1.4 Describe the human body using the anatomical position and specific anatomical terminology.

Study Objective 2: SO 1.4.3 Define the anatomical planes, the anatomical sections, and the directional terms used to describe the human body.

Section Reference 1: Sec 1.4 Basic Anatomical Terminology

Solution: frontal (coronal)

Question type: Text Entry

44) A system consists of related _____ that have a common function.

Answer: organs

Difficulty: Easy

Bloom's: Comprehension

Study Objective 1: SO 1.2 Identify the organ systems and major organs of the human body and describe their locations and functions.

Study Objective 2: SO 1.2.1 Describe the levels of structural organization that make up the human body.

Section Reference 1: Sec 1.2 Levels of Body Organization and Body Systems

Solution: organs

45) The system responsible for movement of limbs, maintenance of posture, and production of heat is the _____ system.

Answer: muscular

Difficulty: Easy

Bloom's: Knowledge

Study Objective 1: SO 1.2 Identify the organ systems and major organs of the human body and describe their locations and functions.

Study Objective 2: SO 1.2.2 Outline the 11 systems of the human body, list the organs present in each, and explain their general functions.

Section Reference 1: Sec 1.2 Levels of Body Organization and Body Systems

Solution: muscular

46) The _____ system enables the body to detect and respond to environmental change through the propagation of impulses.

Answer: nervous

Difficulty: Easy

Bloom's: Knowledge

Study Objective 1: SO 1.2 Identify the organ systems and major organs of the human body and describe their locations and functions.

Study Objective 2: SO 1.2.2 Outline the 11 systems of the human body, list the organs present in each, and explain their general functions.

Section Reference 1: Sec 1.2 Levels of Body Organization and Body Systems

Solution: nervous

47) Regulatory chemicals produced by endocrine glands are called _____.

Answer: hormones

Difficulty: Easy

Bloom's: Knowledge

Study Objective 1: SO 1.2 Identify the organ systems and major organs of the human body and describe their locations and functions.

Study Objective 2: SO 1.2.2 Outline the 11 systems of the human body, list the organs present in each, and explain their general functions.

Section Reference 1: Sec 1.2 Levels of Body Organization and Body Systems

Solution: hormones

48) The right iliac region of the abdomen is _____ to the right lumbar region.

Answer: inferior

Difficulty: Medium

Bloom's: Analysis

Study Objective 1: SO 1.6 Name and describe the abdominopelvic regions and the abdominopelvic quadrants.

Section Reference 1: Sec 1.6 Abdominopelvic Regions and Quadrants

Solution: inferior

49) In the anatomical position, the thumb is _____ to the index finger.

Answer: lateral

Difficulty: Easy

Bloom's: Comprehension

Study Objective 1: SO 1.4 Describe the human body using the anatomical position and specific anatomical terminology.

Study Objective 2: SO 1.4.1 Describe the orientation of the human body in the anatomical position.

Section Reference 1: Sec 1.4 Basic Anatomical Terminology

Solution: lateral

50) A section through the left eyeball that produces equal right and left portions of the eyeball would be a _____ section of the eyeball.

Answer: midsagittal

Difficulty: Easy

Bloom's: Comprehension

Study Objective 1: SO 1.4 Describe the human body using the anatomical position and specific anatomical terminology.

Study Objective 2: SO 1.4.3 Define the anatomical planes, the anatomical sections, and the directional terms used to describe the human body.

Section Reference 1: Sec 1.4 Basic Anatomical Terminology

Solution: midsagittal (median)

51) The _____ pleura lines the external surface of the lungs and the _____ pleura lines the chest wall.

Answer: visceral, parietal

Difficulty: Medium

Bloom's: Application

Study Objective 1: SO 1.5 Describe the major body cavities, the organs they contain, and their associated linings.

Section Reference 1: Sec 1.5 Body Cavities

Solution: visceral, parietal

52) Organs such as the kidneys that are located behind the parietal peritoneum are described as _____ organs.

Answer: retroperitoneal

Difficulty: Easy

Bloom's: Knowledge

Study Objective 1: SO 1.5 Describe the major body cavities, the organs they contain, and their associated linings.

Section Reference 1: Sec 1.5 Body Cavities

Solution: retroperitoneal

53) The large intestine is found in the _____ cavity.

Answer: abdominopelvic

Difficulty: Easy

Bloom's: Knowledge

Study Objective 1: SO 1.5 Describe the major body cavities, the organs they contain, and their associated linings.

Section Reference 1: Sec 1.5 Body Cavities

Solution: abdominopelvic

54) The right lobe of the liver is located in the _____ region of the abdominopelvic cavity.

Answer: right hypochondriac

Difficulty: Medium

Bloom's: Application

Study Objective 1: SO 1.6 Name and describe the abdominopelvic regions and the abdominopelvic quadrants.

Section Reference 1: Sec 1.6 Abdominopelvic Regions and Quadrants

Solution: right hypochondriac

55) The _____ region of the abdominopelvic cavity contains the rectum and the urinary bladder.

Answer: hypogastric

Difficulty: Medium

Bloom's: Application

Study Objective 1: SO 1.6 Name and describe the abdominopelvic regions and the abdominopelvic quadrants.

Section Reference 1: Sec 1.6 Abdominopelvic Regions and Quadrants

Solution: hypogastric

56) The spleen is a(n) _____ organ.

Answer: lymphatic

Difficulty: Medium

Bloom's: Application

Study Objective 1: SO 1.2 Identify the organ systems and major organs of the human body and describe their locations and functions.

Study Objective 2: SO 1.2.2 Outline the 11 systems of the human body, list the organs present in each, and explain their general functions.

Section Reference 1: Sec 1.2 Levels of Body Organization and Body Systems

Solution: lymphatic

57) Oil glands are a component of the _____ system.

Answer: integumentary

Difficulty: Medium

Bloom's: Application

Study Objective 1: SO 1.2 Identify the organ systems and major organs of the human body and describe their locations and functions.

Study Objective 2: SO 1.2.2 Outline the 11 systems of the human body, list the organs present in each, and explain their general functions.

Section Reference 1: Sec 1.2 Levels of Body Organization and Body Systems

Solution: integumentary

58) The spinal cord is a component of the _____ system.

Answer: nervous

Difficulty: Easy

Bloom's: Comprehension

Study Objective 1: SO 1.2 Identify the organ systems and major organs of the human body and describe their locations and functions.

Study Objective 2: SO 1.2.2 Outline the 11 systems of the human body, list the organs present in each, and explain their general functions.

Section Reference 1: Sec 1.2 Levels of Body Organization and Body Systems

Solution: nervous

59) The ureter belongs to the _____ system.

Answer: urinary

Difficulty: Easy

Bloom's: Comprehension

Study Objective 1: SO 1.2 Identify the organ systems and major organs of the human body and describe their locations and functions.

Study Objective 2: SO 1.2.2 Outline the 11 systems of the human body, list the organs present in each, and explain their general functions.

Section Reference 1: Sec 1.2 Levels of Body Organization and Body Systems

Solution: Urinary

60) The larynx belongs to the _____ system.

Answer: respiratory

Difficulty: Medium

Bloom's: Application

Study Objective 1: SO 1.2 Identify the organ systems and major organs of the human body and describe their locations and functions.

Study Objective 2: SO 1.2.2 Outline the 11 systems of the human body, list the organs present in each, and explain their general functions.

Section Reference 1: Sec 1.2 Levels of Body Organization and Body Systems

Solution: respiratory

61) The serous membrane on the external surface of the small intestine is the _____.

Answer: visceral peritoneum

Difficulty: Medium

Bloom's: Application

Study Objective 1: SO 1.5 Describe the major body cavities, the organs they contain, and their associated linings.

Section Reference 1: Sec 1.5 Body Cavities

Solution: visceral peritoneum

Question type: Essay

62) A lymphocyte is an example of which level of body organization?

Answer:

Difficulty: Easy

Bloom's: Application

Study Objective 1: SO 1.2 Identify the organ systems and major organs of the human body and describe their locations and functions.

Study Objective 2: SO 1.2.1 Describe the levels of structural organization that make up the human body.

Section Reference 1: Sec 1.2 Levels of Body Organization and Body Systems

Solution: cellular level

63) The skin along with its derivatives is an example of which level of body organization?

Answer:

Difficulty: Easy

Bloom's: Application

Study Objective 1: SO 1.2 Identify the organ systems and major organs of the human body and describe their locations and functions.

Study Objective 2: SO 1.2.1 Describe the levels of structural organization that make up the human body.

Section Reference 1: Sec 1.2 Levels of Body Organization and Body Systems

Solution: System

64) The salivary glands belong to which level of body organization?

Answer:

Difficulty: Medium

Bloom's: Application

Study Objective 1: SO 1.2 Identify the organ systems and major organs of the human body and describe their locations and functions.

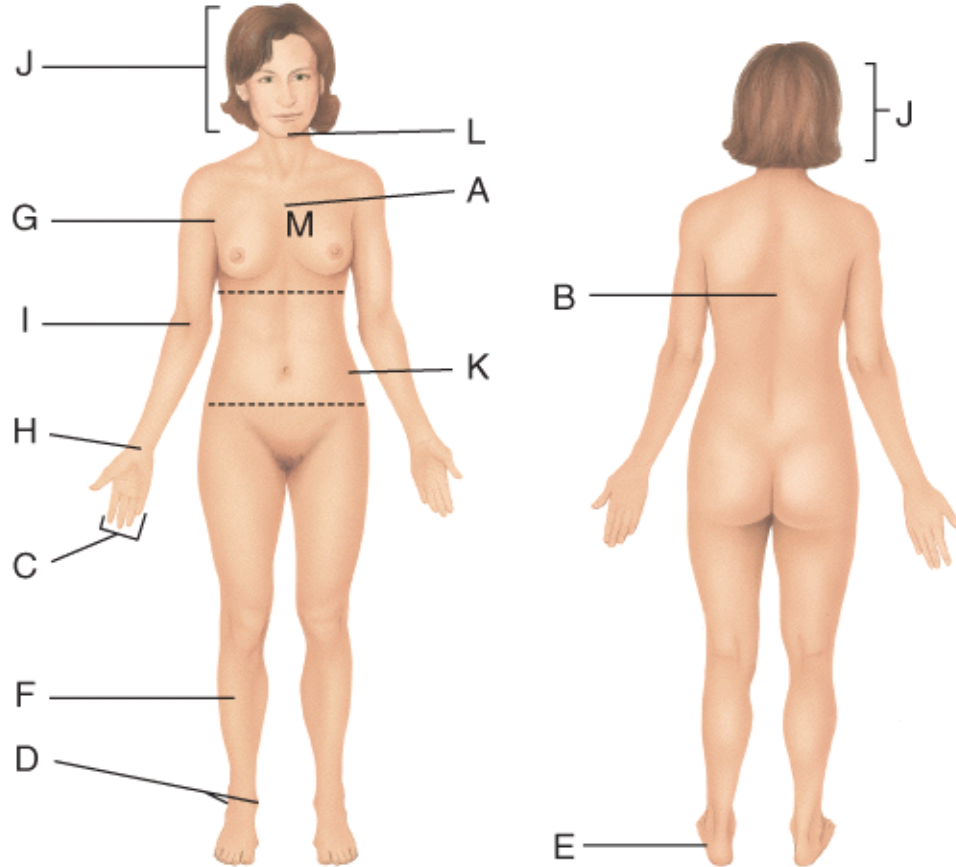
Study Objective 2: SO 1.2.1 Describe the levels of structural organization that make up the human body.

Section Reference 1: Sec 1.2 Levels of Body Organization and Body Systems

Solution: Organ

Question type: Multiple Choice

65) Which letter is pointing to the cephalic region?



- a) L
- b) M
- c) G
- d) J

Answer: d

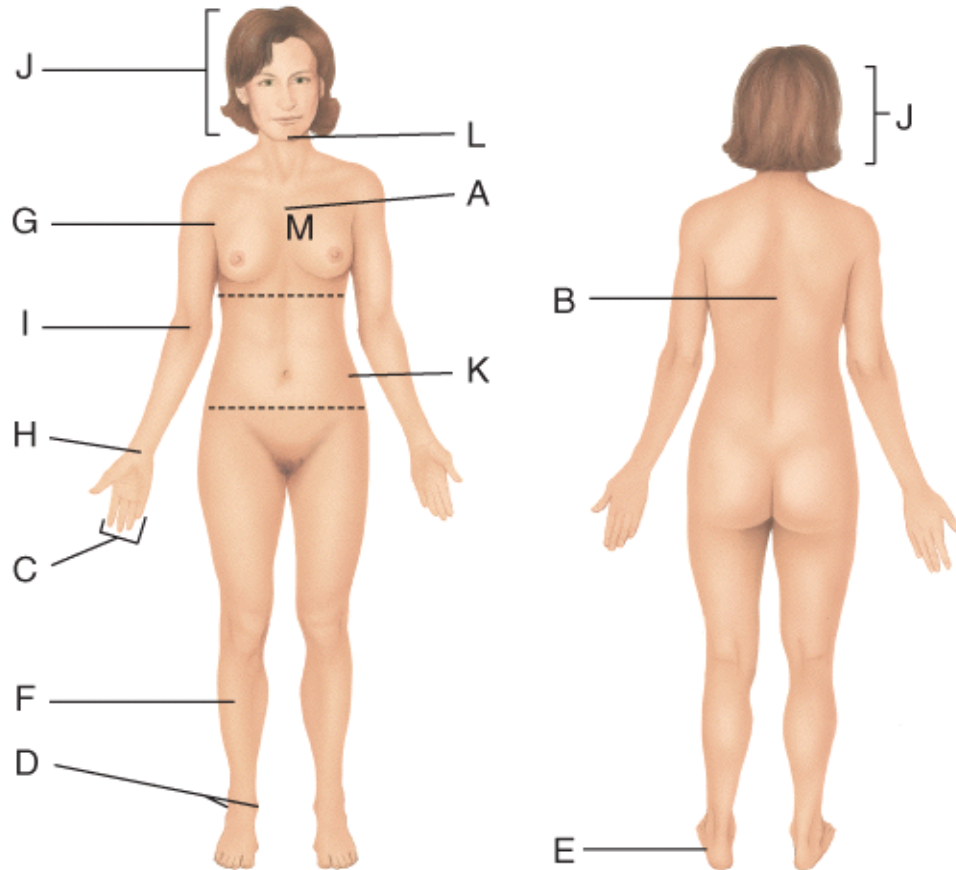
Difficulty: Medium

Bloom's: Comprehension Study Objective 1: SO 1.4 Describe the human body using the anatomical position and specific anatomical terminology.

Study Objective 2: SO 1.4.2 Relate the common names to the corresponding anatomical descriptive terms for various regions of the human body.

Section Reference 1: Sec 1.4 Basic Anatomical Terminology

66) Which letter is pointing to the olecranal region?



- a) K
- b) I
- c) L
- d) E

Answer: b

Difficulty: Medium

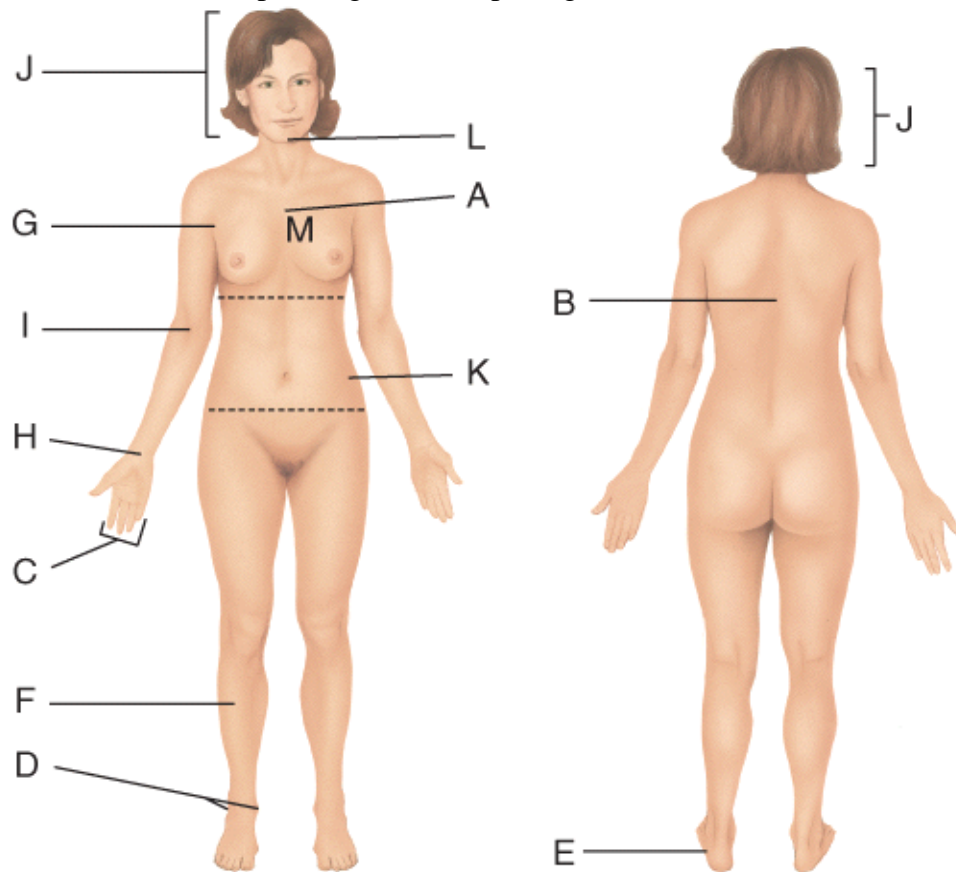
Bloom's: Comprehension

Study Objective 1: SO 1.4 Describe the human body using the anatomical position and specific anatomical terminology.

Study Objective 2: SO 1.4.2 Relate the common names to the corresponding anatomical descriptive terms for various regions of the human body.

Section Reference 1: Sec 1.4 Basic Anatomical Terminology

67) Which letter is pointing to the carpal region?



- a) E
- b) J
- c) H
- d) L

Answer: c

Difficulty: Medium

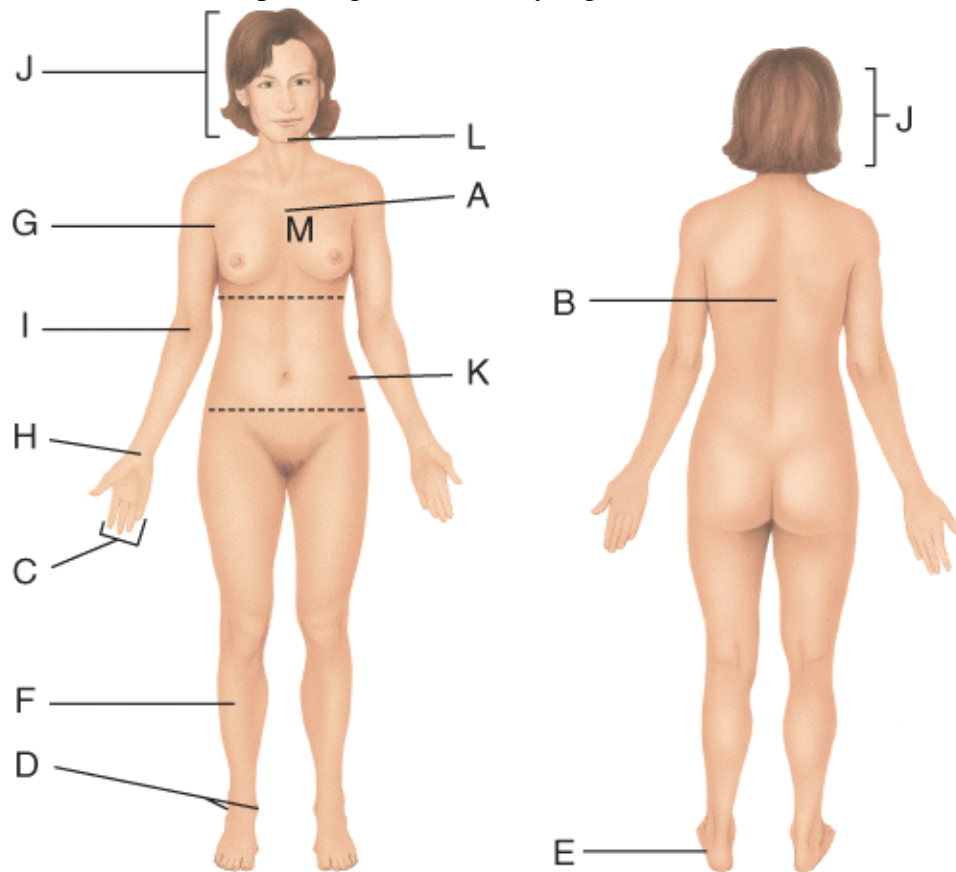
Bloom's: Comprehension

Study Objective 1: SO 1.4 Describe the human body using the anatomical position and specific anatomical terminology.

Study Objective 2: SO 1.4.2 Relate the common names to the corresponding anatomical descriptive terms for various regions of the human body.

Section Reference 1: Sec 1.4 Basic Anatomical Terminology

68) Which letter is pointing to the axillary region?



- a) F
- b) D
- c) I
- d) G

Answer: d

Difficulty: Medium

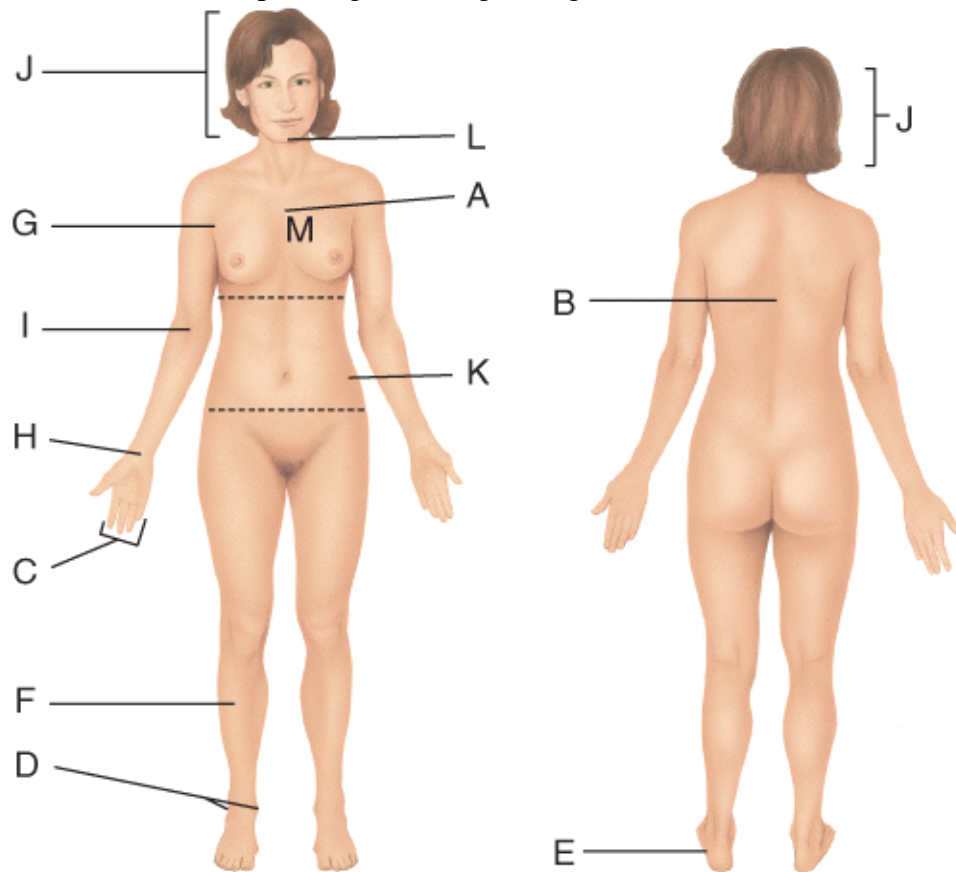
Bloom's: Comprehension

Study Objective 1: SO 1.4 Describe the human body using the anatomical position and specific anatomical terminology.

Study Objective 2: SO 1.4.2 Relate the common names to the corresponding anatomical descriptive terms for various regions of the human body.

Section Reference 1: Sec 1.4 Basic Anatomical Terminology

69) Which letter is pointing to the digital region?



- a) E
- b) C
- c) D
- d) H

Answer: b

Difficulty: Medium

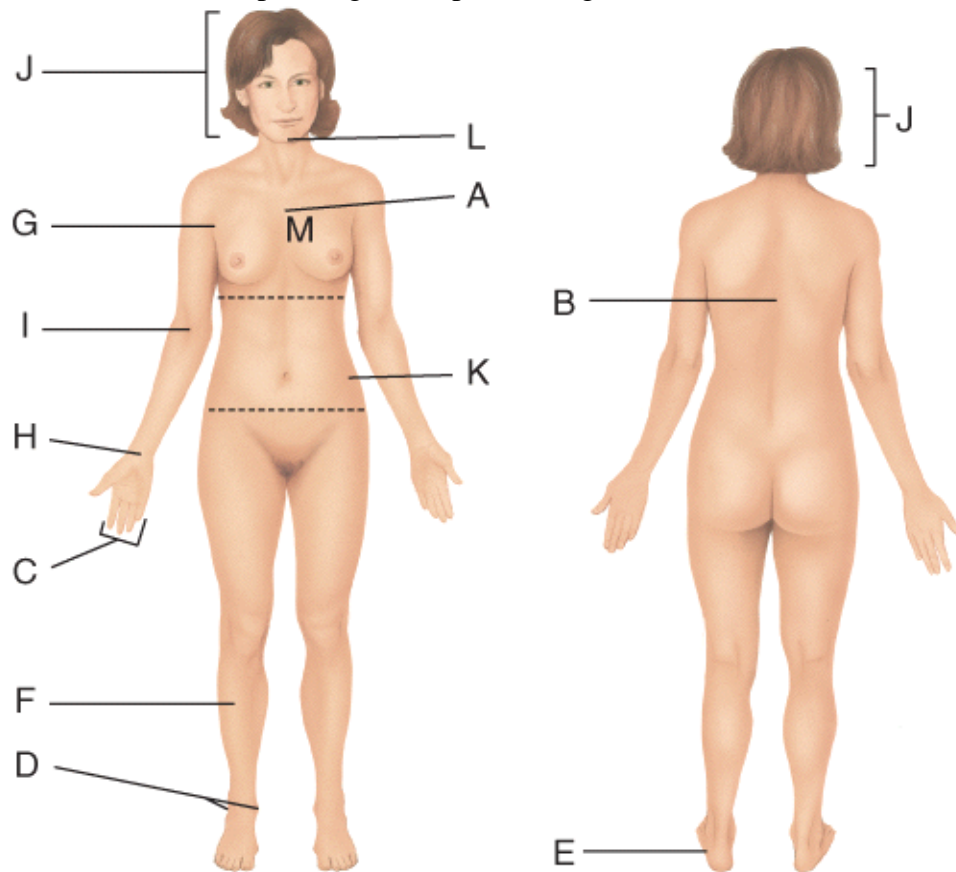
Bloom's: Comprehension

Study Objective 1: SO 1.4 Describe the human body using the anatomical position and specific anatomical terminology.

Study Objective 2: SO 1.4.2 Relate the common names to the corresponding anatomical descriptive terms for various regions of the human body.

Section Reference 1: Sec 1.4 Basic Anatomical Terminology

70) Which letter is pointing to the patellar region?



- a) F
- b) I
- c) A
- d) L

Answer: a

Difficulty: Medium

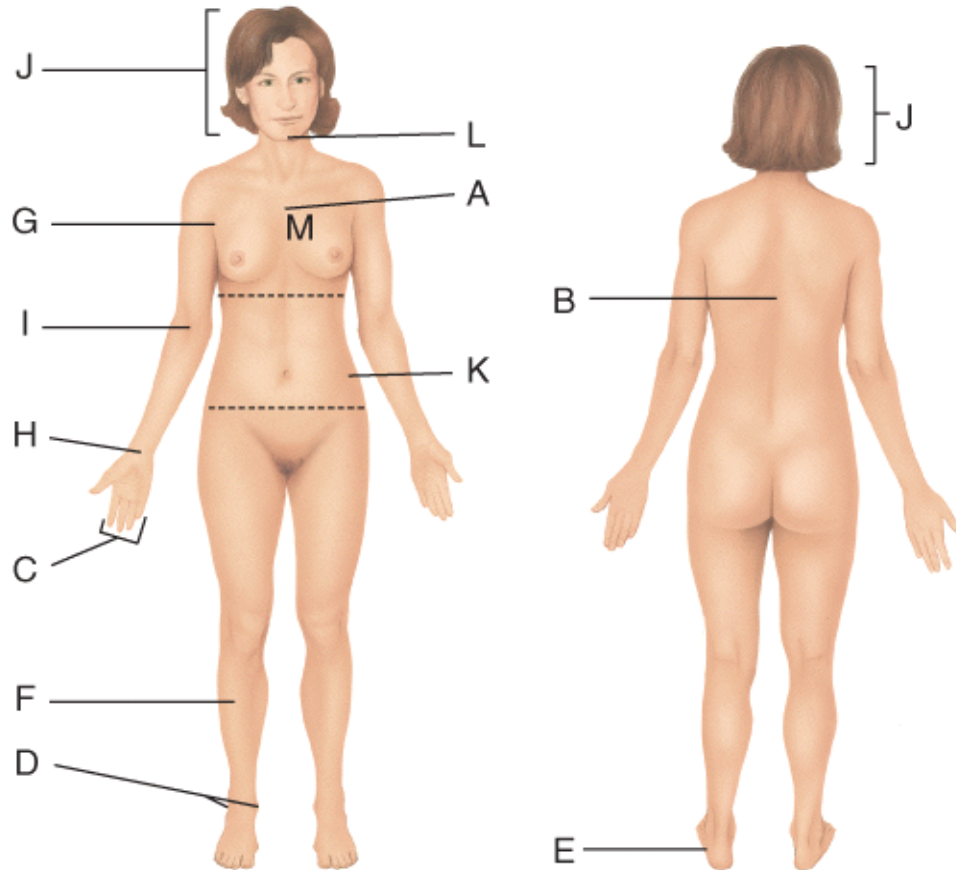
Bloom's: Comprehension

Study Objective 1: SO 1.4 Describe the human body using the anatomical position and specific anatomical terminology.

Study Objective 2: SO 1.4.2 Relate the common names to the corresponding anatomical descriptive terms for various regions of the human body.

Section Reference 1: Sec 1.4 Basic Anatomical Terminology

71) Which letter is pointing to the tarsal region?



- a) F
- b) D
- c) E
- d) G

Answer: b

Difficulty: Medium

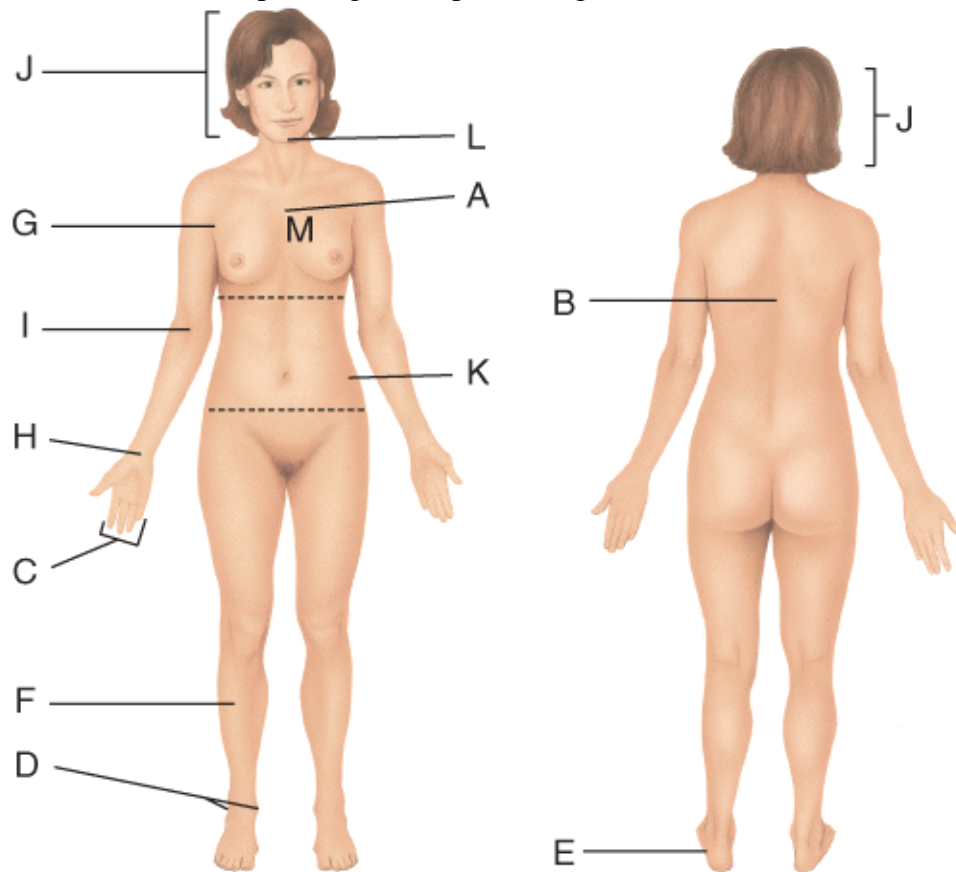
Bloom's: Comprehension

Study Objective 1: SO 1.4 Describe the human body using the anatomical position and specific anatomical terminology.

Study Objective 2: SO 1.4.2 Relate the common names to the corresponding anatomical descriptive terms for various regions of the human body.

Section Reference 1: Sec 1.4 Basic Anatomical Terminology

72) Which letter is pointing to the plantar region?



- a) E
- b) D
- c) F
- d) K

Answer: a

Difficulty: Medium

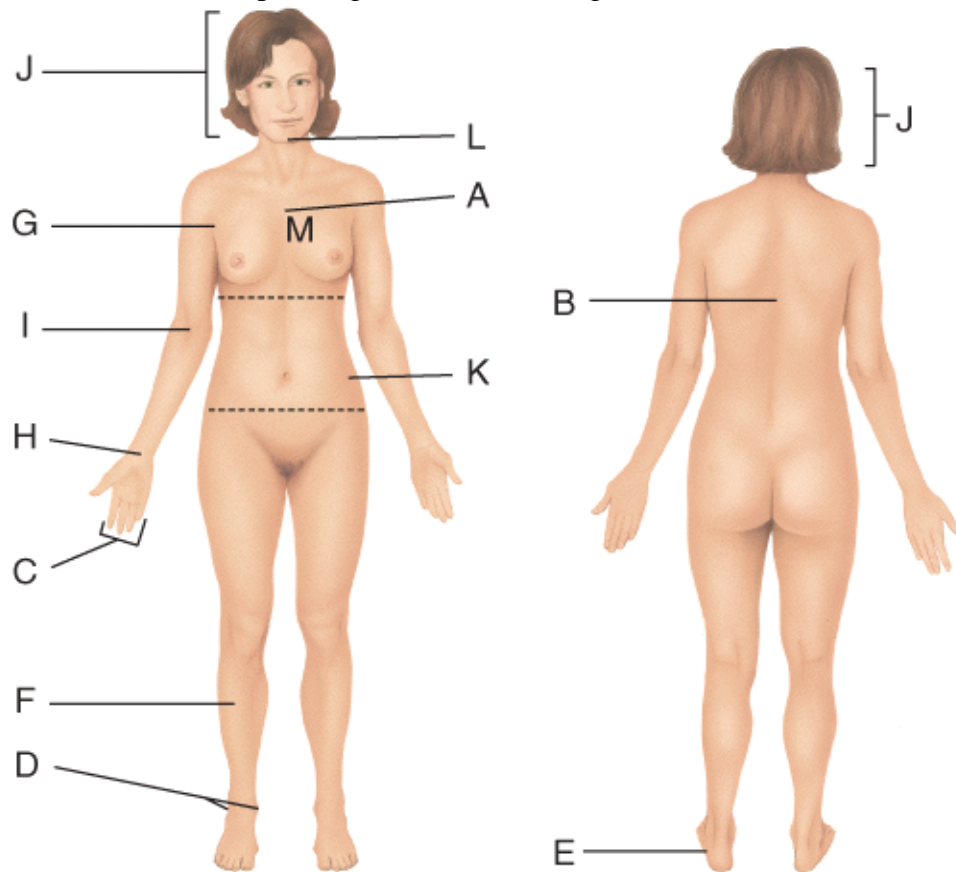
Bloom's: Comprehension

Study Objective 1: SO 1.4 Describe the human body using the anatomical position and specific anatomical terminology.

Study Objective 2: SO 1.4.2 Relate the common names to the corresponding anatomical descriptive terms for various regions of the human body.

Section Reference 1: Sec 1.4 Basic Anatomical Terminology

73) Which letter is pointing to the thoracic region?



- a) C
- b) F
- c) K
- d) M

Answer: d

Difficulty: Medium

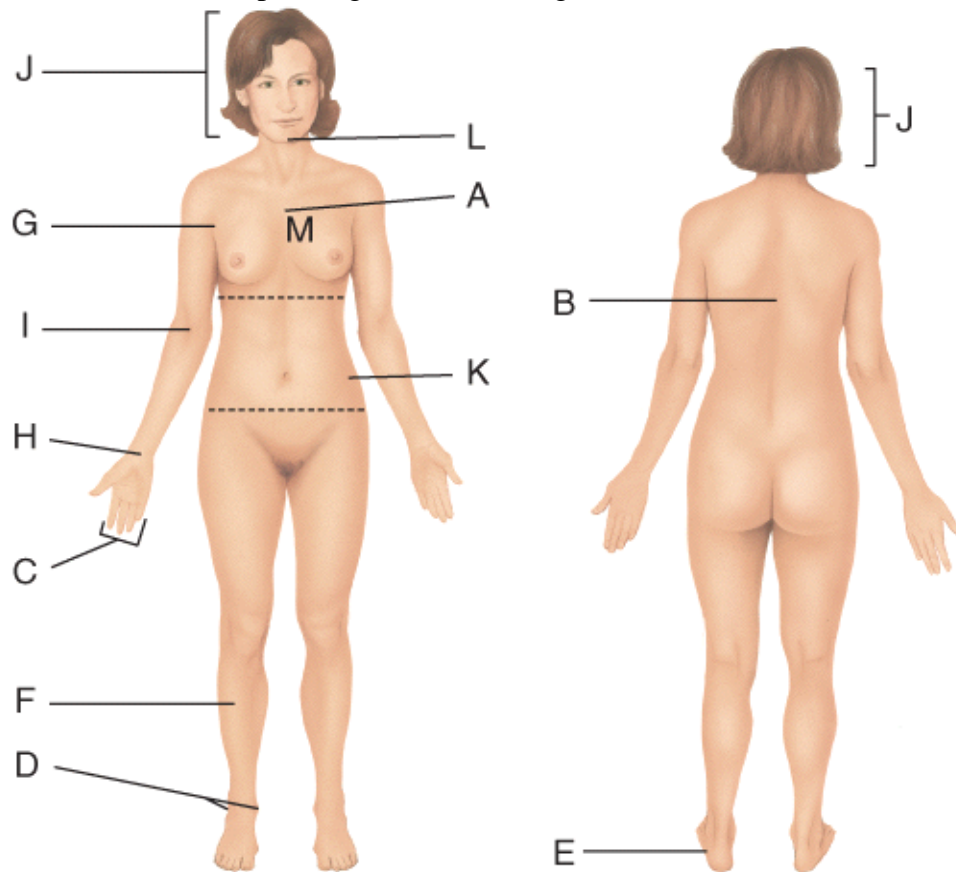
Bloom's: Comprehension

Study Objective 1: SO 1.4 Describe the human body using the anatomical position and specific anatomical terminology.

Study Objective 2: SO 1.4.2 Relate the common names to the corresponding anatomical descriptive terms for various regions of the human body.

Section Reference 1: Sec 1.4 Basic Anatomical Terminology

74) Which letter is pointing to the coxal region?



- a) A
- b) D
- c) K
- d) I

Answer: c

Difficulty: Medium

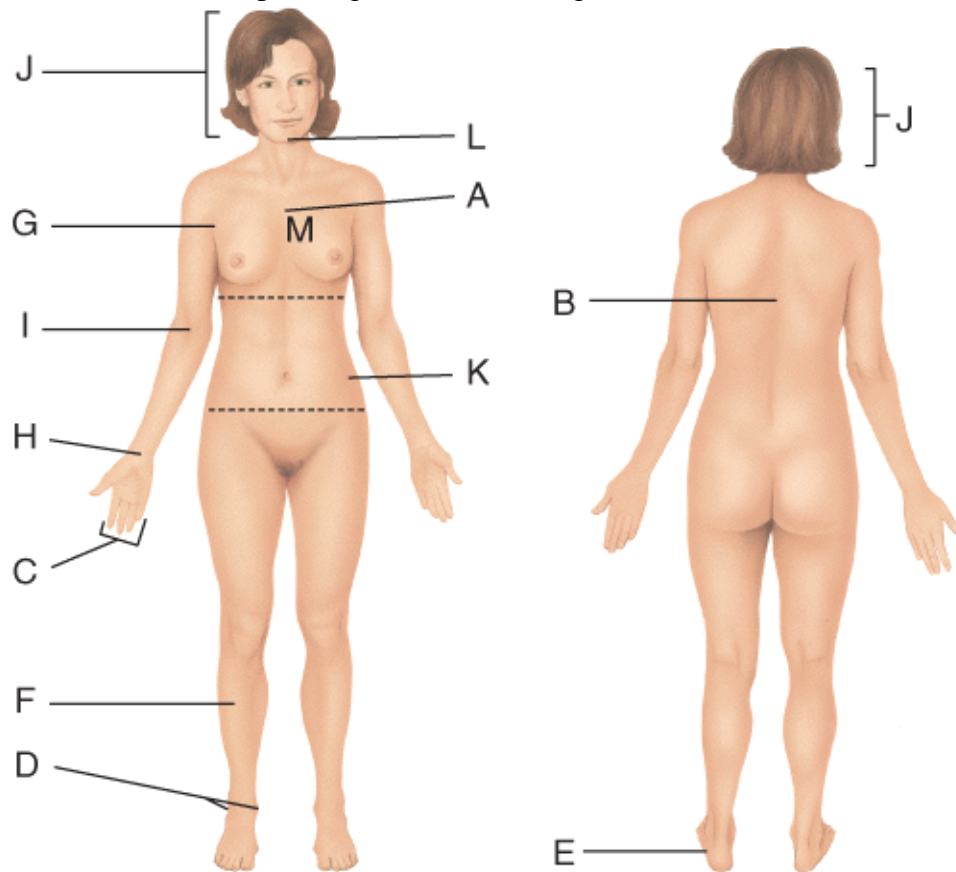
Bloom's: Comprehension

Study Objective 1: SO 1.4 Describe the human body using the anatomical position and specific anatomical terminology.

Study Objective 2: SO 1.4.2 Relate the common names to the corresponding anatomical descriptive terms for various regions of the human body.

Section Reference 1: Sec 1.4 Basic Anatomical Terminology

75) Which letter is pointing to the mental region?



- a) H
- b) B
- c) J
- d) L

Answer: d

Difficulty: Medium

Bloom's: Comprehension

Study Objective 1: SO 1.4 Describe the human body using the anatomical position and specific anatomical terminology.

Study Objective 2: SO 1.4.2 Relate the common names to the corresponding anatomical descriptive terms for various regions of the human body.

Section Reference 1: Sec 1.4 Basic Anatomical Terminology

- 76) Aging is a normal process characterized by a progressive decline in the body's ability to restore
- a. homeostasis
 - b. immunity
 - c. blood pressure
 - d. tissue integrity

Answer: a

Difficulty: Easy

Bloom's: Comprehension

Study Objective 1: SO 1.8 Describe some of the general anatomical and physiological changes that occur with aging.

Section Reference 1: Sec 1.8 Aging

77) The changes associated with aging are apparent in

- a. all body system
- b. the integumentary system
- c. the lymphatic system
- d. the nervous system

Answer: a

Difficulty: Easy

Bloom's: Comprehension

Study Objective 1: SO 1.8 Describe some of the general anatomical and physiological changes that occur with aging.

Section Reference 1: Sec 1.8 Aging

78) Which of the following are NOT changes that occur in the body due to aging?

- a. decreased incidence of heart disease
- b. loss of bone mass
- c. increased susceptibility to cancer
- d. enlarged prostate

Answer: a

Difficulty: Easy

Bloom's: Comprehension

Study Objective 1: SO 1.8 Describe some of the general anatomical and physiological changes that occur with aging.

Section Reference 1: Sec 1.8 Aging